

Case report: Neoplasma kista ovarium

Ego Fernando¹, Nabila Farah Triansa², Hervyasti Purwiandari³

^{1,2,3}Faculty of Medicine, Universitas Tarumanagara, Jakarta, Indonesia

ARTICLE INFO

Article history:

Received Apr 22, 2024

Revised Apr 27, 2024

Accepted Apr 29, 2024

Keywords:

Menstruation
Neoplastic Cysts
Ovarian Cysts

ABSTRACT

Ovarian cysts are fluid-filled sacs that can develop in various body regions, with unknown prevalence due to many cases being asymptomatic. Approximately 4% of women may be hospitalized for an ovarian cyst by age 65. This case report details a 45-year-old woman presenting with abdominal pain during menstruation, an enlarged and hard stomach, a painful breast lump, back pain, defecation difficulties, and discomfort during intercourse. Diagnostic examinations revealed a large ovarian cyst with associated symptoms. Cysts on the ovaries are generally discovered accidentally when the patient is having a routine check-up or other gynecological examination. This is caused by ovarian cysts which can be asymptomatic, especially when they are small. If there is suspicion of an ovarian cyst or a mass is found, it is necessary to continue with a physical examination in the form of TTV, abdominal examination and internal examination. Further research is needed to determine the etiology of ovarian cysts and their treatment.

This is an open access article under the [CC BY-NC](https://creativecommons.org/licenses/by-nc/4.0/) license.



Corresponding Author:

Ego Fernando,
Faculty of Medicine,
Universitas Tarumanagara,
Jl. Letjen S. Parman No.1, RT.6/RW.16, Tomang, District. Grogol Petamburan, West Jakarta City, Special
Capital Region of Jakarta 11440, Indonesia
Email: egofernando30@gmail.com

INTRODUCTION

Cysts are abnormal structural growths in the form of fluid-filled sacs that can grow in certain parts of the body and come in various types (Heddy et al., 2023; Mulyanto & Yanti, 2020). Ovarian cysts, or cystoma ovarii, are a type of benign tumor that grows inside or on the surface of the ovaries and is filled with fluid or semisolid material of varying sizes (Mobeen & Apostol, 2022; Mounir et al., 2022).

The true prevalence of ovarian cysts is unknown (Mimoune et al., 2021; Sasidharan et al., 2021), as many patients are believed to be asymptomatic and undiagnosed, and the prevalence depends on the population studied. About 4% of women will be hospitalized for an ovarian cyst by age 65 (Eisenberg et al., 2021). In a random sample of 335 asymptomatic women aged 24 to 40 years, the prevalence of adnexal lesions was 7.8%. Another study examining ovarian cysts in postmenopausal women showed a prevalence of 2.5% for simple unilocular adnexal cysts. In a survey of 33,739 premenopausal and postmenopausal women, 46.7% had adnexal cysts on transvaginal ultrasound, with 63.2% showing resolution of the abnormality on subsequent ultrasound. In postmenopausal women, 18% may develop one or more Graffian follicles, which

appear as cysts on imaging. Most of these cysts are benign (Kowalski & Okoye, 2020). Mature cystic or dermoid teratomas represent more than 10% of all ovarian neoplasms. Ovarian cysts are the most common tumors in babies and fetuses, with a prevalence of more than 30%. In the United States, ovarian carcinoma is diagnosed in more than 21,000 women each year, causing 14,600 deaths (Mobeen & Apostol, 2022).

Cysts on the ovaries are generally discovered accidentally when the patient is undergoing a routine check-up or other gynecological examination (Akbar et al., 2020; Suryoadji et al., 2022). This is caused by ovarian cysts, which can be asymptomatic, especially when they are small (Albers et al., 2020). Large ovarian cysts can generally cause symptoms such as feeling bloated, feeling full easily, wanting to urinate, and pain in the stomach (Suryoadji et al., 2022). In ovarian cysts that have become malignant, the symptoms can be more varied due to the possibility of metastasis, both in the area around the abdomen and even reaching the breasts. Symptoms that can be found in malignant ovarian cysts include malaise, weight loss, pain in the affected area (abdominal pain or chest pain), and difficulty breathing (Hanbidge et al., 2004).

Because benign ovarian cysts are generally asymptomatic, a good clinical approach is needed regarding the patient's complaints (Lotfy et al., 2024; Movva & Kavya, 2021; Poplawski & Ma, 2022). An understanding of the onset, duration, triggers, and characteristics needs to be studied properly to be able to determine the severity of ovarian cysts. Apart from anamnesis based on complaints and physical findings, family history and risk factors are also important to ask. A family history of similar complaints or a history of finding ovarian cysts needs to be explored. Menstrual history, whether or not there is pain during menstruation, increased menstrual blood volume, and shortening of the menstrual cycle also need to be asked in cases of suspected ovarian cysts. Obstetric history also needs to be explored, considering the association between pregnancy and ovarian cysts. Surgical history and use of contraception also need to be asked (WHO, 2023).

RESEARCH METHOD

In this study, the research method used was a case study. The data used included information from the patient's medical history, physical examination, diagnostic test results such as CT-Scan and abdominal ultrasound, as well as information regarding the symptoms felt by the patient. Data were collected through interviews with patients, direct examination by medical personnel, and interpretation of diagnostic test results. Additional variables such as family medical history and previous treatment history were also used. The data collected was then analyzed descriptively to identify the symptoms, diagnosis, and management of ovarian cyst neoplasm in the case.

RESULTS AND DISCUSSIONS

The patient came to the emergency room at K.R.M.T. Wongsonegoro Regional Hospital on June 12, 2023, with complaints of abdominal pain during menstruation about a month ago. The pain is felt to come and go for about 15 minutes in all parts of the stomach; the pain is like being stabbed. The patient's stomach appears to be enlarged. The patient also complained that there was a lump in the left breast; the lump had been painful for 2 years. Patients also complain of back pain, difficulty defecating, and discomfort during sexual intercourse.

The patient had previously sought treatment at the Meranggen clinic, then was referred to Pelita Hospital for an abdominal ultrasound. From the results of the ultrasound, a cyst was found on the ovary. Then, after that, he was referred to Wongsonegoro Hospital. The patient has never experienced similar complaints. The patient's history of HT, DM, and asthma was denied. The patient had experienced abortion five times. The family history of similar diseases, namely diabetes mellitus, heart disease, asthma, allergies, and hypertension in the patient's family, was denied. Patients rarely control their food intake every day. The patient is often active. The patient works as a farmer, and the hospital costs are paid by BPJS. The patient menarched at the age of 12 years. The

patient's menstrual cycle is 28-30 days with a duration of 6 days. Patients change sanitary napkins three to four times per day. The patient was married once, at the age of 21 years, for 24 years. On physical examination, it was found that the stomach appeared enlarged and felt hard. On the CT-Scan supporting examination, a lobulated cystic lesion with clear borders and regular edges was found in the pelvic cavity-abdomen on the superoanterior aspect of the uterus (size LL 37.01 x AP 24.82 x CC 30.04 cm) with a picture of an ovarian cyst. Then, during an ultrasound examination of the abdomen, it was found that there was a very large cyst that could not be measured by the probe coming from the pelvic cavity and extending to the abdominal cavity and ovarian cystoma. Laboratory examination revealed leukocytosis and hypocalcemia.

Table 1. Hematology laboratory result (14 July 2023)

| Parameter | Result | Normal range |
|-----------------|--------|--------------|
| Leukocyte count | 14,6 | 3,6 - 11,0 |
| Calsium | 0,75 | 1,00 - 1,15 |

Lobulated cystic lesion with clear borders and regular edges in the pelvic cavity and abdomen on the superoanterior aspect of the uterus (size LL 37.01 x AP 24.82 x CC 30.04 cm). After contrast injection, no visible enhancement was observed; the lesion appears to be pushing the intestine superiorly and laterally, pushing the liver and pancreas superiorly, and attaching to the transverse and descending colon.

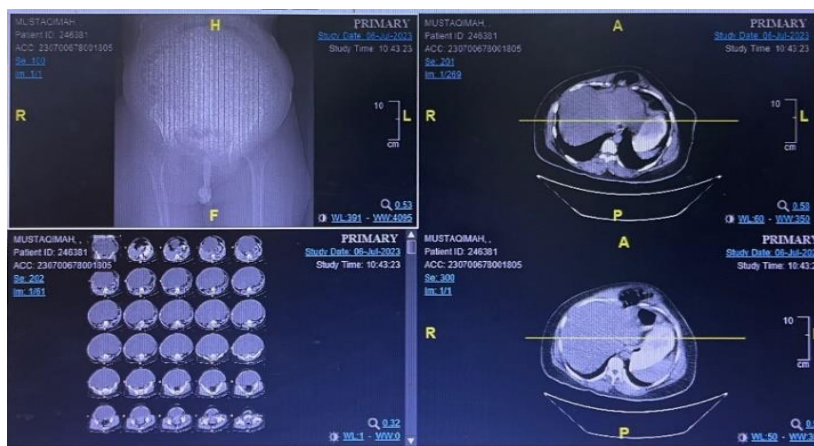

Figure 1. Abdominal CT-Scan (06 July 2023)

Impression: There is a very large cyst that cannot be measured by the probe, originating from the pelvic cavity and extending into the abdominal cavity and ovarian cystoma.

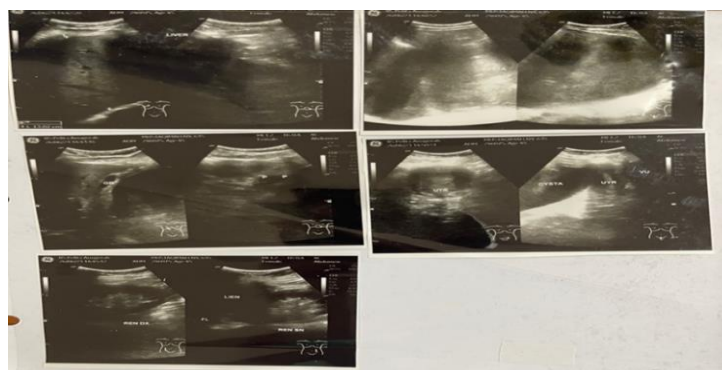


Figure 2. USG Abdomen (26 June 2023)

Impression: There is a very large cyst that cannot be measured by the probe, originating from the pelvic cavity and extending into the abdominal cavity and ovarian cystoma.

Cysts are abnormal structural growths in the form of fluid-filled sacs that can grow in certain parts of the body and come in various types. Ovarian cysts, or cystoma ovarii, are a type of benign tumor that grows inside or on the surface of the ovaries and is filled with fluid or semisolid material of varying sizes (Mobeen & Apostol, 2022).

The ovaries are internal genital organs whose function is to produce female germ cells known as ova and female sex hormones, namely estrogen and progesterone. Each oval-shaped ovary measures 1.5 x 0.75 inches, or 4 x 2 cm, and is attached to the back of the broad ligament by the mesovarium. The ovaries are usually located in front of the lateral walls of the pelvis, in a depression called the ovarian fossa, bordered above by the external iliac arteries and veins and behind by the internal iliac arteries and veins. However, the location of the ovaries varies greatly and is often found hanging downward in the retrouterine excavation (Douglas cavity). During pregnancy, the enlarging uterus pulls the ovaries upward into the abdominal cavity. After delivery, as the broad ligament relaxes, the ovaries assume varying positions within the pelvis. The ovaries are surrounded by a thin, fibrous capsule called the tunica albuginea. On the outside, this capsule is covered by a modified layer of peritoneum called the germinal epithelium. The term germinal epithelium is inaccurate because this layer does not produce ova. Oogonia develop during the fetal period from primordial germ cells. Before puberty, the surface of the ovaries is smooth. After puberty, the surface of the ovary progressively wrinkles as a result of continuous degeneration of the corpus luteum. After menopause, the ovaries shrink, and their surface becomes pitted and scarred.

Ovarian arterial bleeding, namely the ovarian artery (He et al., 2024), originates from the abdominal aorta at the level of the first lumbar vertebra. Ovarian venous bleeding, namely the right ovarian vein, empties into the inferior vena cava, while the left ovarian vein empties into the left renal vein. The ovarian lymph vessels follow the ovarian arteries and drain their lymph to the para-aortic nodes at the level of the lumbar vertebra. The innervation of the ovaries comes from the aortic plexus and follows the course of the ovarian arteries. Bleeding, lymph flow, and ovarian innervation pass through the superior pelvic aperture and cross the external iliac arteries and veins. These vessels and nerves reach the ovaries by passing through the lateral side of the broad ligament known as the ovarian suspensory ligament. The vessels and nerves finally enter the hilum of the ovary through the mesovarium (Snell, 2012).

Ovarian cysts can arise due to excessive stimulation of gonadotropins, including: (1) gestational trophoblastic neoplasm (Abdulloh & Ni'mah, 2023) (hydatidiform mole, choriocarcinoma); (2) ovarian function where excessive ovulation occurs, which causes the ovarian surface epithelium to undergo neoplastic changes; (3) exposure to carcinogens, radioactive substances, exogenous viruses, and polycystic hydrocarbons; (4) in patients undergoing infertility treatment, where ovulation induction is carried out through hormonal manipulation. Risk factors for ovarian cysts are a history of previous ovarian cysts, irregular menstrual cycles, increased distribution of upper body fat, early menstruation, fertility levels, hypothyroidism or hormonal imbalance, and tamoxifen therapy for mammary cancer. Meanwhile, in solid tumors, the exact etiology is unknown; it is thought to be due to abnormalities in embryonal cell growth or the genetic nature of the cancer, which is triggered by free radicals or carcinogenic substances (DeCherney & Nathan, 2013).

Clinical symptoms of ovarian cysts in the early stages can include menstrual disorders; if they are pressing on the rectum or vagina, there may be constipation or frequent urination; there can be stretching or pressure on the pelvic area, which causes spontaneous pain and pain in the stomach; and pain during intercourse. In this patient, the symptoms felt were back pain, difficulty defecating, and discomfort during sexual intercourse.

Cysts on the ovaries are generally discovered accidentally when the patient is having a routine check-up or other gynecological examination. This is caused by ovarian cysts, which can be asymptomatic, especially when they are small. Large ovarian cysts can generally cause symptoms such as feeling bloated (Raja & Suresh, 2023), feeling full easily, wanting to urinate, and pain in the stomach. In ovarian cysts that have become malignant, the symptoms can be more varied due to the possibility of metastasis, both in the area around the abdomen and even reaching the breasts. Symptoms that can be found in malignant ovarian cysts include malaise, weight loss, pain in the affected area (abdominal pain or chest pain), and difficulty breathing (Hanbidge et al., 2004).

Because benign ovarian cysts are generally asymptomatic, a good clinical approach is needed regarding the patient's complaints. An understanding of the onset, duration, triggers, and characteristics needs to be studied properly to be able to determine the severity of ovarian cysts. Apart from anamnesis based on complaints and physical findings, family history and risk factors are also important to ask. A family history of similar complaints or a history of finding ovarian cysts needs to be explored. Menstrual history, whether or not there is pain during menstruation, increased menstrual blood volume, and shortening of the menstrual cycle also need to be asked in cases of suspected ovarian cysts. Obstetric history also needs to be explored, considering the association between pregnancy and ovarian cysts. Surgical history and use of contraception also need to be asked (WHO, 2023).

If there is suspicion of an ovarian cyst or a mass being found, it is necessary to continue with a physical examination. In this case, the physical examinations that can be carried out are TTV, abdominal examination, and internal examination. If the cyst has enlarged, a mass or lump may be felt on abdominal examination. The description of the mass that needs to be given includes location, size, boundaries, density, mobility, and whether or not there is pain. During the internal examination, an inspection, inspeculo, VT, or RT examination is carried out to determine the mass in the adnexal area (WHO, 2023).

CONCLUSION

Cysts on the ovaries are generally discovered accidentally when the patient is having a routine check-up or other gynecological examination. This is caused by ovarian cysts which can be asymptomatic, especially when they are small. If there is suspicion of an ovarian cyst or a mass is found, it is necessary to continue with a physical examination in the form of TTV, abdominal examination and internal examination. Further research is needed to determine the etiology of ovarian cysts and their treatment.

Limitations of this study include the limited sample size of only one case, limited generalizability of the findings, patient information that may be incomplete, diagnostic methods that are not described in detail, and lack of information regarding treatment and post-diagnosis follow-up. Thus, this study highlights the need for further research with a more comprehensive study design to gain a deeper understanding of ovarian cyst neoplasms and their management strategies.

References

- Abdulloh, A., & Ni'mah, A. Q. (2023). BI-RADS Classification For Breast Ultrasound: A Review. *Pharmacology, Medical Reports, Orthopedic, and Illness Details (COMORBID)*, 2(2), 67-84. <https://doi.org/10.55047/comorbid.v2i2.840>
- Akbar, M. I. A., Tjokroprawiro, B. A., & Hendaro, H. (2020). *Ginekologi praktis komprehensif* (Vol. 2). Airlangga University Press.
- Albers, C. E., Ranjit, E., Sapra, A., Bhandari, P., & Wasey, W. (2020). Clinician beware, giant ovarian cysts are elusive and rare. *Cureus*, 12(1), 1-8. <https://doi.org/10.7759/cureus.6753>
- DeCherney, A. H., & Nathan, L. (2013). *Current Obstetry and Gynecology Diagnosis and Therapy*. McGraw-Hill.
- Eisenberg, N., Volodarsky-Perel, A., Brochu, I., Tremblay, C., Gorak, E., Hudon, E., Fortin, S., Kogan, L., &

- Rivard, C. (2021). Short-and long-term complications of intraoperative benign ovarian cyst spillage: a systematic review and meta-analysis. *Journal of Minimally Invasive Gynecology*, 28(5), 957-970. <https://doi.org/10.1016/j.jmig.2020.11.025>
- Hanbidge, A. E., Buckler, P. M., O'Malley, M. E., & Wilson, S. R. (2004). From the RSNA refresher courses: imaging evaluation for acute pain in the right upper quadrant. *Radiographics*, 24(4), 1117-1135.
- He, Z., Ma, L., Dan, W., Cai, X., Liu, H., Mao, L., Zhou, X., Li, G., Ding, C., & Wang, T. (2024). Anomalous origin of the left suprarenal, inferior phrenic arteries and left ovarian artery in a human cadaver. *Anatomical Science International*, 99(1), 146-150. <https://doi.org/10.1007/s12565-023-00738-2>
- Heddy, H., Jamilah, N., & Zulhijjah, A. (2023). FAKTOR-FAKTOR YANG BERHUBUNGAN DENGAN KEJADIAN KISTA OVARIUM PADA WANITA USIA SUBUR DI POLI BKIA RUMAH SAKIT KENCANA KOTA SERANG. *JURNAL ILMIAH OBSGIN: Jurnal Ilmiah Ilmu Kebidanan & Kandungan P-ISSN: 1979-3340 e-ISSN: 2685-7987*, 15(1), 354-363.
- Kowalski, A., & Okoye, E. (2020). *Breast Cyst*.
- Lotfy, A. M., Gonied, A. S., Mohamed, S. L., & Abd El Monem, M. M. (2024). Effect of Ovarian Cysts on Women Health Related Quality of Life. *Zagazig Nursing Journal*, 20(1), 81-93. <https://doi.org/10.21608/ZNJ.2024.336837>
- Mimoune, N., Azzouz, M. Y., Khelef, D., & Kaidi, R. (2021). Ovarian cysts in cattle: a review. *Veterinarska stanica*, 52(5), 587-603. <https://doi.org/10.46419/vs.52.5.10>
- Mobeen, S., & Apostol, R. (2022). Ovarian Cyst. 2022 May 1. *StatPearls [Internet]. Treasure Island (FL): StatPearls Publishing*.
- Mounir, B., Yassine, E., Bensardi, F., & Abdelaziz, F. (2022). Incidental discovery of a giant ovarian cystadenoma. *Annals of Medicine and Surgery*, 82. <https://doi.org/10.1016/j.amsu.2022.104698>
- Movva, N., & Kavva, M. (2021). Ovarian Cysts in Post Hysterectomy Cases-An Overview. *Sch Int J Obstet Gynec*, 4(5), 182-186. <https://doi.org/10.36348/sijog.2021.v04i05.002>
- Mulyanto, A., & Yanti, F. (2020). Implementasi Case Based Reasoning Untuk Diagnosa Penyakit Kista Ovarium Dengan Metode Bayes Menggunakan Codeigniter Di Klinik Mutiara Sehat Bekasi. *Jurnal Informatika SIMANTIK*, 5(1), 1-7.
- Poplawski, R., & Ma, K. (2022). Benign ovarian cysts in premenopausal women. *Obstetrics, Gynaecology & Reproductive Medicine*, 32(10), 234-239. <https://doi.org/10.1016/j.ogrm.2022.08.003>
- Puspita, A., & Munir, M. A. (2021). CASE REPORT: TREATMENT OF OVARIAN CYSTS WITH TOTAL HYSTERECTOMY AND BILATERAL SALFINGOOFERECTOMY. *Jurnal Medical Profession (Medpro)*, 3(2).
- Raja, P., & Suresh, P. (2023). Variety of ovarian cysts detection and classification using 2D Convolutional Neural Network. *Multimedia Tools and Applications*, 1-19. <https://doi.org/10.1007/s11042-023-17439-7>
- Sasidharan, J. K., Patra, M. K., Singh, L. K., Saxena, A. C., De, U. K., Singh, V., Mathesh, K., Kumar, H., & Krishnaswamy, N. (2021). Ovarian cysts in the bitch: An update. *Topics in Companion Animal Medicine*, 43, 100511. <https://doi.org/10.1016/j.tcam.2021.100511>
- Snell, R. S. (2012). Anatomi klinis berdasarkan sistem. *Jakarta: EGC*, 87-92.
- Suryoadji, K. A., Ridwan, A. S., Fauzi, A., & Kusuma, F. (2022). DIAGNOSIS DAN TATALAKSANA PADA KISTAA OVARIUM: LITERATURE REVIEW. *Khazanah: Jurnal Mahasiswa*, 14(1).
- WHO. (2023). *Magnetic resonance imaging units (per million population), total density*. World Health Organization.